

REVIEW

Vasectomy

W.-H. Weiske

Private Practice, Stuttgart, Germany

Key words. Clearance of spermatozoa—long-term effects of vasectomy—postvasectomy complications—surgical procedure—volume of post-operative ejaculate

Summary. Vasectomy is regarded as the safest method now available for male fertility control. Almost 100 million men worldwide have relied on vasectomy for family planning. This review discusses all currently relevant operative techniques, including no-scalpel vasectomy, complications, possible long-term effects on the testis and epididymis, and diseases for which associations with vasectomy have been suggested, such as arteriosclerosis, autoimmune diseases and cancer of the prostate and testis. Other topics of discussion include the timing of post-operative semen analysis, patient noncompliance concerning post-operative controls, persistent cryptozoospermia and transient reappearance of spermatozoa after vasectomy, vasectomy failure and legal aspects.

Introduction

Vasectomy is the safest method now available for male fertility control. In 1991, the number of sterilized men was estimated to be 50 million worldwide (WHO, 1991). Since then, 60 million men have reportedly undergone vasectomy by means of the no-scalpel method alone (Arellano *et al.*, 1997). Although precise numbers are currently not available, it is assumed that more than 100 million men have chosen vasectomy as a means of birth control. In Germany, vasectomy accounts for 2% of all contraceptive methods, while the worldwide rate is 10% (WHO, 1991). In Germany, the woman still bears the main burden of contraception (pill 60%; coil 10%). In

the USA, nearly 7% of all married couples choose vasectomy as their form of birth control.

The global increase in the acceptance of vasectomy as the most effective means of male family planning has naturally stimulated intense interest in the consequences of this procedure. Vasectomy and its sequelae are therefore amongst the most studied areas of modern medicine.

This review discusses currently relevant operative techniques, complications, and possible long-term effects on the testis and epididymis, as well as diseases suggested to be associated with vasectomy.

Information and legal situation

Voluntary vasectomy, for the purpose of family planning, is readily accessible. There are no legal regulations concerning the age or size of family for which sterilization is permitted. Pre-operative information is a decisive factor, with special consideration given to the patient's age, his marital situation or partner relationship and his irrevocable decision to seek permanent contraception, because there will never be a refertilization rate of 100%.

All alternative options for preventing pregnancy should be discussed, as well as side-effects and risks. Consultation with the wife or partner is desirable, although it is not legally required that the wife agrees to the intervention. It is most important to inform the patient of the necessity for post-operative ejaculate analyses, because the success of the operation cannot be confirmed without two subsequent demonstrations of azoospermia. Insufficient control of the ejaculate is the most frequent cause of unintended pregnancy after vasectomy.

Correspondence: Dr Wolf-Hartmut Weiske, König-Karl-Str. 38, 70372 Stuttgart, Germany. Tel: +49 711568090; Fax: +49 711564046; E-mail: WeiskeWH@t-online.de

The patient must also be informed that spermatozoa may reappear in the ejaculate as a result of spontaneous recanalization. Paternity as a consequence of recanalization can occur at any time after vasectomy and does not depend on the surgical procedure (Verhulst & Hoekstra, 1999). It has proved useful that these points be confirmed by the patient's consent in the form of a signature.

Surgical procedures

A vasectomy technique should provide maximum safety as regards sterility (azoospermia) and minimal post-operative complications. The operation is usually performed as an outpatient procedure under local anaesthesia. From a medical point of view there is no reason to perform vasectomy under full anaesthesia. Vasectomy reversal surgery if desired (considering a divorce rate of more than 30%) should not be impeded by excessive resection of the deferent duct.

The method most commonly used in Germany, the ligation technique (Fig. 1), consists of identification of the vas, resection of 2–4 cm, ligation of the vas ends and turning the ends round into a U-shape. In hundreds of vasectomy reversal procedures on our own patients, this U-shaped part of the vas deferens has never been observed. It appears that pressure-related necrosis occurs in these segments of the vas deferens, so that finally there is only scar tissue (Fig. 2). As a logical consequence of this

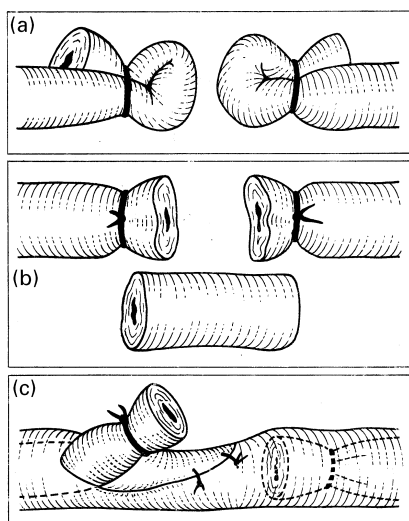


Figure 1. Techniques of vasectomy by resection and ligation of the vas ends. (a) Ligation of the U-shaped vas ends. (b) Ligation of the vas ends and resection of vas deferens (2–4 cm). (c) Interposition of fascia so both ends are in different layers.

observation, the 'U-turn' of the vas ends appears to be unnecessary.

The fulguration technique inaugurated by Schmidt (1966) consists of thermal damage to the mucosa of the vas deferens by insertion of a diathermic needle, resulting in cicatricial occlusion via an inflammatory reaction. The two ends of the vas deferens are fulgurated over a distance of about 1 cm. A U-shaped segment of the vas is resected and the testicular remnant is ligated (Weiske, 1994). This procedure offers the advantage of being minimally invasive, which results in an extremely low complication rate (0.3% haematoma) (Schmidt & Free, 1978; Schmidt, 1995). This means that the patient does not require analgesics and can return to normal activity after only 1 day. Another advantage is that tissue damage is restricted to the ends of the deferent duct, thus creating optimal conditions for reversal of vasectomy, as observed in 12 of our own patients.

The best-known minimal invasive technique is the 'no-scalpel vasectomy' from China (Li *et al.*, 1991). By means of a special clamp, the skin covering the vas deferens is perforated and separated, followed by opening of the sheath layer. Thereafter, the vas is grasped with special forceps. The subsequent procedure is similar to that of the fulguration technique described above. This method is currently the least traumatic procedure, and is increasingly being used worldwide (Holt & Higgins, 1996; Skriver *et al.*, 1997; Kumar *et al.*, 1999; Sokal *et al.*, 1999), because the complication rate of 0.4% is much lower than that after conventional vasectomy (3.4%), although in the 'good hands' of an experienced surgeon the incidence of complications for no-scalpel vasectomy is virtually the same as that for the standard incision method (0.3%)

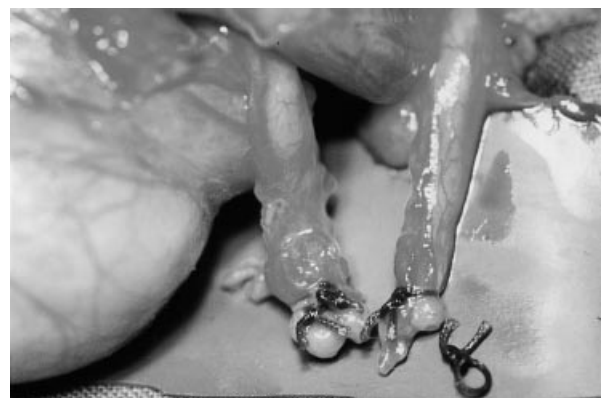

Figure 2. Findings during reversal of vasectomy performed 29 h before via ligation of the U-shaped vas ends. Ligation decreases the blood circulation in the vas ends and the tissue becomes necrotic. One of the threads is already free and two open lumina of the vas are visible.

(Alderman & Morrison, 1999). In 1995, about 494 000 vasectomies were performed in the USA, in 29% of which the no-scalpel method was used (Haws *et al.*, 1998). Since then, more than 60 million no-scalpel vasectomies have been performed in 26 countries (Arellano *et al.*, 1997).

To date, open-ended vasectomy, the clip technique and occlusion techniques (acrylate and polyurethane elastomere) have not been generally accepted in Europe. Either the methods are considered not safe enough (open-ended vasectomy presenting with a failure rate of 4%; Shapiro & Silber, 1979; Goldstein, 1983), or the use of agents for chemical vas occlusion poses pharmacological problems. However, Australian authors (Errey & Edward, 1986) have reported only one failure (0.02%) in 4330 open-ended vasectomies, so this method cannot be generally rejected. Tissue interposition between the ends of the vas was essential. This method was developed to avoid epididymal congestion and thus the occurrence of sperm granulomas (Shapiro & Silber, 1979).

Recently, vasectomy has also been performed by laparoscopy procedures. In our opinion, the related expenditure and risks are only justified in combination with another indication, such as surgical hernia repair (Kasirajan *et al.*, 1999).

A review of the literature demonstrates that vasectomy is successful in 97.2 to 99% of all cases, irrespective of the method used. Most statistics show a failure rate of less than 1% (Smith, 1996; Schwingl 2000). It seems that interposition of connective tissue between the two ends of the vas, rather than the length of the resected part, is crucial for success (Hallan & May, 1988). An additional factor that should not be underestimated is the experience and skill of the surgeon. Physicians who do not perform many vasectomies have higher complication rates (Kendrick *et al.*, 1987).

Histological examination of the excised vas segment?

To fulfil the need for safety, it is a common procedure to have the resected part examined histologically to show that the vasectomy was performed properly. This measure is not legally required. It causes unnecessary expense without providing significant benefits. In case of a so-called identification error, the first semen analysis will show numerous motile spermatozoa which will continue to appear in follow-up examinations. This costly practice will not protect the patient from late recanalization.

The reason for repeated vasectomy is actually a matter of indifference to him.

From a legal point of view, histological examination of the resected part of the vas deferens proves only that the vasectomy was carried out on the structure of the vas. It does not provide any information on whether the surgical procedure itself was properly done.

Post-operative complications

Whether there are any post-operative complications will primarily depend on the surgeon's experience rather than on the method used. The percentages shown in Table 1 have been reported (Leader *et al.*, 1974; Philip *et al.*, 1984; Kendrick *et al.*, 1987).

Post-vasectomy pain syndrome is a well-recognized clinical entity. Reports of pain involving the testis and epididymis after vasectomy over a long period of time, worsening during sexual activity, are in the range of 3–8% (Myers *et al.*, 1997). Common conservative therapy includes scrotal support, nonsteroidal anti-inflammatory drugs and spermatic cord block. In severe cases, surgical treatment has been reported, including vasectomy reversal, open-ended vasectomy (decreasing hydrostatic pressure in the epididymis), epididymectomy and, as a last resort, orchiectomy, which has a cure rate of up to 76% (Myers *et al.*, 1997). Among our own patients, similar complaints have been noted only occasionally in more than 2000 vasectomized men; the patients complaining of pain were always treated conservatively.

Post-operative semen analysis

Post-vasectomy semen examination always consists of analysis of the sediment of the ejaculate, in order that single spermatozoa should not be overlooked (2000 r.p.m. for 10 min). Different

Table 1. Post-operative complication percentages

Complication	Percentage
Haematoma	0.04–18.0
Epididymitis	0.4–6.1
Ligature abscess	0–5.6
Cutaneous abscess	0–2.7
Infection	0–6.0
Sperm granuloma	5–70.0
Hydrocele	0–4.0
Vas cutaneous adhesion	0–2.0
Spontaneous late recanalization	0–6.0

recommendations have been made concerning the number and time of post-operative semen analyses for assessment of the surgical results. Data in the literature range from one to three follow-ups, at intervals of 6 weeks, for up to 1 year. The number of ejaculations appears to be essential. In a study of 13 vasectomized men (Freund & Davis, 1969), the patients were asked to produce 10 ejaculations within the shortest possible time. Absence of spermatozoa was noted after 6–10 ejaculates following vasectomy. Apart from the additional technical demand, this natural clearance of the seminal duct may be one of the reasons why irrigation of the abdominal vas segment with nitrofurazone or bidistilled water, inaugurated by Albert & Seebode (1977) and in Germany promoted by Carl (1998), has not gained general acceptance.

In one of the most extensive studies (Alderman, 1989) comprising 5233 vasectomized men with at least 12 post-operative ejaculations, azoospermia was observed only after 3, 6 and 12 months in 75, 90 and 99% of cases, respectively. These results may be explained by the age of the patients and their frequency of intercourse.

The 1999 guidelines of the German Society of Urology recommend the following procedure. The first post-operative semen analysis is made after 6 weeks and with at least 12 ejaculations, because the seminal duct is thought to be cleared of residual spermatozoa by that time (Freund & Davis, 1969; Maatman *et al.*, 1997). Eight per cent of vasectomized men are found to be azoospermic at first follow-up (Goldstein, 1995). A second examination is performed after 12 weeks. If sediment analysis reveals that both ejaculates are devoid of spermatozoa, the operation is regarded as successful, clinically and legally. A third control after 6 months is recommended to enable recognition of early recanalization. The second control is important as it may reveal reappearance of sperm cells in some men (8%) who were found to be azoospermic on first examination (De Kniff *et al.*, 1997).

If motile spermatozoa are present in samples taken after 6 weeks, this is indicative of spontaneous recanalization because sperm cells become immotile after 3 weeks at the latest (Goldstein, 1995). Therefore, these must be 'younger' cells that are related to the epididymis.

It has occasionally been recommended that annual semen analyses should be carried out to screen for the rare patients with late recanalization (Maatman *et al.*, 1997). Considering the attendant expense and the extremely low

probability of a positive semen analysis, this demand is unlikely to be met.

Patient noncompliance after vasectomy

The importance of post-vasectomy semen analyses is discussed in broad terms with each patient. The man then signs an agreement that he can only be considered infertile after two consecutive negative semen analyses. Likewise, the physician is not legally liable until azoospermia has been demonstrated twice. It is therefore surprising how vasectomized patients behave with regard to the requested follow-ups; they are noncompliant rather than compliant. 14–36% of the men never returned for a semen analysis (Belker *et al.*, 1990; Weiske, 1994; Maatman *et al.*, 1997). One or two examinations were performed in approximately one-third of cases. Only 3% of the patients were seen at the recommended yearly follow-up (Maatman *et al.*, 1997). The partners of eight of 1892 vasectomized men experienced pregnancy (Maatman *et al.*, 1997). None of the eight men met the criterion of two consecutive negative semen analyses 1 month apart.

No studies are available on the reasons for this noncompliance. Possible causes include psychological factors such as aversion to masturbation, confidence in the physician who certainly has done a good job, and finally the low failure rate of less than 1%, which is also known to the patient. Changes in the partner relationship and health problems causing inability to perform intercourse may also play a role. But perhaps it is simply because of the irresponsible carelessness of vasectomized men that post-operative follow-up examinations are missed.

Persistent cryptozoospermia after vasectomy

In rare cases, azoospermia is not achieved even after 6 months or longer. The sediment continues to contain immotile, and sometimes even motile, spermatozoa, indicating cryptozoospermia or severe OAT syndrome. The anatomical background for this observation is very small channels and slits in the connective tissue and scar tissue between the vas ends, especially in the case of chronic inflammation (Fig. 3). The problem is how the patient should be advised. First of all, it is important to consider whether his spermatozoa are motile or immotile. The risk of pregnancy with nonmotile spermatozoa has been estimated to be less than that with

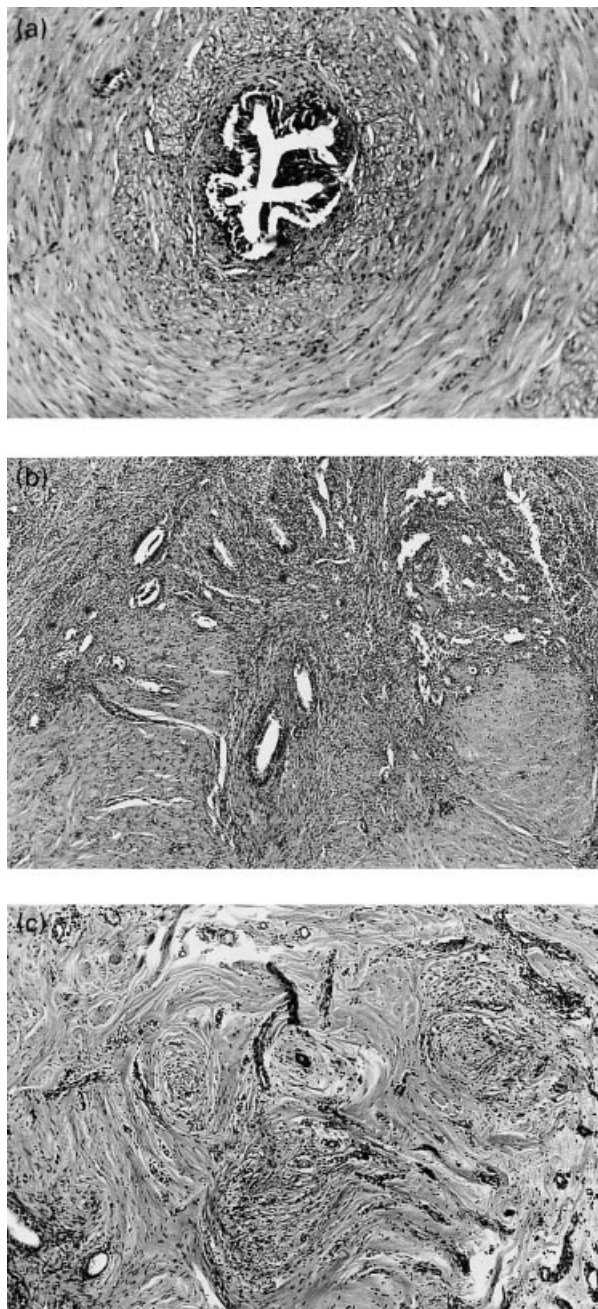


Figure 3. Cross-sections of the testicular ends of the vas during vasectomy reversal. (a) Normal cross-section of the vas deferens with intact intratubular mucosa of the inner lumen. (b) Cross-section closer to the vas end shows scar tissue with very small 'channels' and slits, partially covered by prismatic epithelia (regenerated ducts). These regenerated new small ducts could be the cause of so-called late regeneration, followed by spermatozoa in the ejaculate. (c) Cross-section of the final part of the vas end showing mostly scar tissue with signs of chronic inflammation. At the left margin is a typical regenerated duct covered with prismatic epithelia. These findings were obtained up to the abdominal end of the vas.

spontaneous late recanalization (Benger *et al.*, 1995). Motile spermatozoa are a typical sign of the continuity of the seminal duct and, consequently, revasectomy should be performed. Men with immotile spermatozoa could be offered a special clearance, provided the risk of pregnancy

is properly discussed and documented. If the patient wishes for 'a hundred per cent' safety, a repeat operation is mandatory. A 'wait-and-see approach' is also possible, especially in consideration of the partner's fertility status. Spontaneous azoospermia can even occur several years later (Alderman, 1989).

Transient reappearance of spermatozoa after vasectomy

Smith *et al.* (1994) reported paternity after vasectomy despite negative semen analyses. Births occurred 1–5 years after vasectomy. In all cases, post-operative semen analyses (two or three) and those after conception had been negative. Therefore, spermatozoa must have passed through in the meantime. A possible explanation for this phenomenon can be derived from histomorphological investigations of deferent duct tissue at the site of previous vasectomy (Fritz & Weiske, 1996). More than 75% of vas ends examined showed signs of persistent chronic inflammation, and 20% showed signs of ductal regeneration products in the sense of 'microrecanalization' (Freund *et al.*, 1989). It is feasible that regeneration products in combination with chronic inflammation allow intermittent passage of spermatozoa, resulting in transient fertility of the affected man. This thesis is supported by a study on the occurrence of spermatozoa in the ejaculate before vasectomy reversal. Spermatozoa were demonstrated in more than 90% of the ejaculates after ultracentrifugation, and in 9.7% after common sediment analysis (Lemack & Goldstein, 1996). Our own investigations on conventionally centrifuged ejaculates obtained before vasectomy reversal revealed occasional, immotile, dead (eosin staining) spermatozoa in three of 100 patients (unpublished data).

Causes of vasectomy failure

The most frequent cause of undesired pregnancy after vasectomy is unprotected intercourse prior to demonstration of azoospermia. Spontaneous recanalization is considered a rare event; a distinction should be made between early recanalization in the first 3 months, i.e. before post-operative azoospermia is achieved, and late recanalization after demonstration of azoospermia. In individual cases, recanalization was observed 5–8 years after vasectomy (Alderman, 1989), but these are extremely rare events. The histological structure related to recanalization presents ductal regeneration products in the

sense of sperm granuloma and very seldom an open vas deferens (Fig. 2).

Vasectomy failure can also be caused by a so-called identification error, which means that it was not the vas deferens but another structure (e.g. the vas) that was operated on. In such cases, post-operative clearance of sperm cells will never occur, and a repeat operation will be necessary to ensure severance of the vas deferens.

Ejaculate volume before and after vasectomy

The ejaculate consists of a mixture of secretions from the seminal vesicles (60%), the prostate (30%) and Cowper's and Littre's glands (5%), as well as the testis and epididymis (5%). The frequent patient concern of reduced volume or even absence of ejaculate after vasectomy is therefore unfounded. A significant post-operative reduction in ejaculate volume is virtually never found, as shown by examination of pre- and post-vasectomy semen analyses in 204 men undergoing vasectomy (Weiske, 1994). Pre-operative semen analysis revealed a mean volume of 2.87 ml (0.8–7.8 ml) as against 2.58 ml (0.8–6.2 ml) after the operation. This is a difference of 0.29 ml or 10%. Taking the largest post-operative volumes for evaluation, a mean value of 3.29 ml is obtained, which is markedly higher than that before operation. A possible reason for this difference is that obtaining ejaculate on the day of operation was stressful.

Vasectomy and reproductive tract

Following vasectomy, the testis continues to produce spermatozoa. Because of the occluded vas deferens, there is only limited space for these spermatozoa (epididymis and convoluted part of the vas), which leads to increased intraluminal pressure, especially in the epididymis. The fate of the epididymis depends on the elasticity of the epididymal tubule, the amount of spermatozoa produced, and the resorptive capacity of the epididymis. The pressure built up in the epididymis is not transmitted to the testis so the seminiferous tubules are unaffected. Therefore, spermatogenesis remains unchanged (Weiske & Schulze, 1996; Weiske, 2000). In this respect, there is a significant difference between humans and animals, some species of which show severe testicular alterations up to testicular atrophy after vasectomy (Aydos *et al.*, 1998; Whyte *et al.*, 1998). In humans, the epididymis is the vulnerable

organ as the rise of pressure in the epididymal tubules can lead to ruptures ('blow-outs') and subsequent formation of sperm granuloma (Flickinger *et al.*, 1994; McDonald, 1996). The probability of the occurrence of such epididymal blow-outs increases with the interval since vasectomy, reaching a critical point after 10 years.

The significance of phagocytosis of epididymal spermatozoa by intraluminal macrophages is still unclear (McDonald, 1996). It is a known fact that some men undergoing vasectomy reversal have no spermatozoa during the operation but later show normal semen analysis. Since there is obviously no epididymal obstruction in these cases, clearance of spermatozoa by phagocytosis may be a plausible explanation.

By contrast, vasectomized animals may show severe alterations. While the epididymis of rabbits and guinea pigs can distend significantly so that sperm granuloma are seldom demonstrable, rats, with lower distensibility of the epididymal tract, show ruptures and formation of sperm granuloma as early as 3 weeks after the operation.

Alleged long-term effects of vasectomy

Immunological effects

Approximately 70% of vasectomized patients develop anti-sperm antibodies (Heidenreich *et al.*, 1994), with a maximum after 6–8 weeks (Flickinger *et al.*, 1994). This is a classic immune response to antigens. Spermatozoa are antigens because of the blood–testis barrier and the fact that they are produced after immune system development. In the majority of patients, the anti-sperm antibody titre gradually declines to moderate values. In our own studies on more than 500 men who requested vasectomy reversal, significantly increased serum anti-sperm antibody titres were observed in 13% of the patients.

Arteriosclerosis

The assumption that arteriosclerosis develops more extensively in vasectomized men is based on a study on monkeys (Alexander & Clarkson, 1978). On a high-fat diet, arteriosclerotic changes in the cerebral arteries were more pronounced in animals that had been vasectomized. In an extensive study (Massey *et al.*, 1984), 10 590 vasectomized patients were compared with the same number of nonvasectomized men (same age and race) and examined for 54 diseases of

the large organs. The median vasectomy interval was 7.9 years; 3436 men had been vasectomized more than 10 years before. The results of the study showed a similar or lower rate of cardiovascular diseases, neoplasms and immune-related diseases in the vasectomized group. Diabetes mellitus and general mortality were lower in the vasectomized group. A slightly higher morbidity rate in vasectomized men was noted for epididymitis and orchitis. These results were confirmed by further studies in smaller patient groups, so it can be stated today that vasectomy is not associated with an increased risk of arteriosclerosis or autoimmune diseases.

A study by Manson *et al.*, (1999) included 22 071 US physicians aged 40–84 years. Of the 4546 men with vasectomy, 1159 had undergone the procedure at least 15 years previously. The results of this study provide reassuring evidence that vasectomy does not increase the risk of cardiovascular disease, even 15 or more years following the procedure.

Vasectomy and hormone metabolism

Testosterone production by Leydig cells remains unaffected by vasectomy (Association for Voluntary Sterilization, 1980). A multiethnic case-control study (John *et al.*, 1995) revealed lower serum concentrations of sex hormone-binding globulin (SHBG) and a higher ratio of dihydrotestosterone to testosterone in vasectomized men than in nonvasectomized control subjects. Similar results indicating a significant elevation of dihydrotestosterone levels in vasectomized men were obtained in a pilot study by Mo *et al.* (1995). This altered endocrine profile in vasectomized men needs further evaluation in longitudinal studies. To date there is no biological indication of why vasectomy alone should influence the conversion rate of testosterone to dihydrotestosterone.

Vasectomy and psychological alterations

Concerning psychological alterations, these are usually changes that already existed before vasectomy. An extensive pre-operative discussion can elucidate psychological problems and consequently allow consideration of whether vasectomy should be performed at a later date or not at all.

Vasectomy and testicular cancer

Studies concerning carcinoma of the testis are controversial. In all investigations where a

positive relation between testicular cancer and vasectomy was demonstrated, this was related to epidemiological causes. Statistically it is very difficult to establish a significant correlation, particularly because the incidence of testicular carcinoma is 2–8 per 100 000 men. In a large cohort study of more than 73 000 men, no increased risk of testicular cancer after vasectomy was observed (Møller *et al.*, 1994). Testicular cancer originates from carcinoma *in situ* (CIS). It is believed that CIS is a malignant gonocyte formed during embryogenesis. Vasectomy might precipitate the development of testicular cancer from the pre-invasive CIS lesion (Jørgensen *et al.*, 1993).

Vasectomy and cancer of the prostate

In two cohort studies (Giovannucci *et al.*, 1993a, b) and another two investigations (Mettlin *et al.*, 1990; Rosenberg *et al.*, 1990) it was found that vasectomized men have an increased risk of developing prostate cancer. Patients with a vasectomy interval of more than 20 years are thought to be particularly affected (Giovannucci *et al.*, 1992). With regard to mortality, there were no significant differences. Later 'population-based case-control studies' (John *et al.*, 1995; Zhu *et al.*, 1996) failed to demonstrate that vasectomized men are at increased risk of the development of prostatic carcinoma. Rosenberg *et al.* (1994) concluded that the present data provide little support for a connection between vasectomy and the risk of prostate cancer or other carcinomas.

Bernal-Delgado *et al.* (1998) performed a meta-analysis of all essential studies on vasectomy and prostate cancer in the literature; the authors concluded that there is no causal relation between prostatic carcinoma and vasectomy.

Similarly, a recent population-based control study in Massachusetts (Lesko *et al.*, 1999) did not confirm the hypothesis that vasectomy increases the risk of prostate cancer in men older than 55 years.

Why were such different results obtained regarding this important issue? Differences may be due to bias in selection of study participants and study controls, in obtaining information about study participants (questionnaire, telephone interview, etc.) and in confounding the vasectomy-prostate cancer relationship. In the USA and Western Europe, vasectomy is performed by urologists. Therefore, pre-operative rectal examination and check-ups are more likely to be performed in these patients than in

men who are not operated on by a urologist. In their meta-analysis, Bernal-Delgado *et al.* (1998) observed a significantly higher risk of prostate carcinoma (PCA) after vasectomy in hospital-based studies (relative risk=1.98; 95% confidence interval 1.37–2.86) and no increased risk in population-based studies (relative risk=1.12; 95% confidence interval 0.96–1.32).

Vasectomized men are more sexually active, have better health and live longer (Giovannucci *et al.*, 1992). Therefore, they are seen less frequently in hospitals than nonvasectomized men. However, a prolonged life is associated with the risk of developing PCA in old age. In a recent editorial by Peterson & Howards (1998) from the Atlanta National Center for Chronic Disease Prevention and Health Promotion, it was concluded that ‘... the results of studies on vasectomy–prostate cancer relationship are inconsistent and the observed associations among most positive studies are weak in epidemiologic terms’. Thus, the alleged causal relationship between vasectomy and PCA remains doubtful, and is likely to be dismissed in the near future, as was the suggested association between vasectomy and arteriosclerosis, which took 10 years to be disproved. Therefore, it is not surprising that couples, especially in the USA, continue to regard vasectomy as a safe and simple method of contraception (Piccinino & Mosher, 1998; Magnani *et al.*, 1999).

In a statement by the American Association of Urology, which was supported by the German Society of Urology, it was recommended that preventive examinations should be performed from the age of 40 onwards. At present there is no reason for vasectomized men to undergo reversal of vasectomy. However, prior to vasectomy the patient should be informed about pertinent studies, leaving the final decision to him.

A prostate cancer risk factor analysis in more than 500 000 men in a national study of prostate-specific antigen failed to demonstrate a relationship between prostate carcinoma and vasectomy (Stone *et al.*, 1994).

Is vasectomy of long-term benefit?

About 5% of vasectomized men consider undergoing vasectomy reversal (Engelmann *et al.*, 1989). In 90% of these cases, a new marriage to a younger woman and a wish for children are the reasons. Considering a divorce rate of up to 50% in Western countries, this percentage is rather low, suggesting that vasectomized men have stable partnerships; otherwise, the wish for

reversal would be expected to be much higher than 5%.

Vasectomy reversal procedures, performed in specialized centres, are very successful, offering patency rates from 75 to 95% and pregnancy rates between 40 and 75% (Weiske, 2000). The costs of these operations are lower than those of contraceptives during the average vasectomy interval of 7–9 years (Jequier, 1998; Pryor, 1998). In our opinion, it is not justified to have ejaculates cryopreserved before vasectomy, as has occasionally been recommended (Jequier, 1998), because 95% of vasectomized men never wish reversal. Furthermore, cryopreservation would cause additional expense which would amount to the cost of reversal, taking the average vasectomy interval of 7–9 years as a basis. There is another, quite different reason for refusing pre-operative cryopreservation. The patient’s decision for vasectomy must be definite at the time of operation. The offer of cryopreservation diminishes its seriousness, leaving a ‘back door’ which is not conducive to profound decision-making.

References

- Albert PS, Seebode J (1977) Nitrofurantoin: Vas irrigation as adjunct in vasectomy. *Urology* 10:450–451.
- Alderman PM (1989) General and anomalous sperm disappearance characteristics found in a large vasectomy series. *Fertil Steril* 51:859–862.
- Alderman PM, Morrison GE (1999) Standard incision or no-scalpel vasectomy? *J Fam Pract* 48:719–721.
- Alexander NJ, Clarkson ZB (1978) Vasectomy increases the severity of diet-induced atherosclerosis in *Macaca fascicularis*. *Science* 201:538–541.
- Arellano LS, Gonzalez BJL, Hernandez OA, Moreno AO, Espinosa PJ (1997) No-scalpel vasectomy: review of the first 1,000 cases in a family medicine unit. *Arch Med Res* 28:517–522.
- Association for Voluntary Sterilization (1980) Current status of the endocrinological effects of vasectomy. *Biomed Bull* 1:1–5.
- Aydos K, Soygur T, Kupeli B, Unsal A, Tolunay O, Erdem E, Guven C, Kupeli S (1998) Testicular effects of vasectomy in rats: an ultrastructural and immunohistochemical study. *Urology* 51:1051–1056.
- Belker AM, Sexter MS, Sweitzer SJ, Raff MJ (1990) The high rate of noncompliance for post-vasectomy semen examination: medical and legal considerations. *J Urol* 144:284–286.
- Benger AU, Swami SK, Gingell JC (1995) Persistent spermatozoa after vasectomy: a survey of British urologists. *Br J Urol* 76:376–379.
- Bernal-Delgado E, Latour-Pérez J, Pradas-Arnal F, Gómez-López LI (1998) The association between vasectomy and prostate cancer: a systematic review of the literature. *Fertil Steril* 70:191–200.
- Carl P (1998) Bemerkungen zur Arbeit von S. Kliesch *et al.* *Urologe B* 38:275.
- De Kniff DW, Vrijhof HJ, Arends J, Janknegt RA (1997) Persistence or reappearance of nonmotile sperm after

- vasectomy: does it have clinical consequences? *Fertil Steril* 67:332–335.
- Engelmann U, Deindl F, Hertle F, Wilbert D, Senge T (1989) Die Refertilisierungssituation in der Bundesrepublik Deutschland—Ergebnisse einer Umfrage. *Urologe B* 29:29–33.
- Errey BB, Edward IS (1986) Open-ended vasectomy: an assessment. *Fertil Steril* 43:843.
- Flickinger CJ, Herr JC, Baran ML, Howards SS (1994) Testicular development and the formation of spermatic granulomas of the epididymis after obstruction of the vas deferens in immature rats. *J Urol* 154:539–1544.
- Freund M, Davis JE (1969) Disappearance rate of spermatozoa from the ejaculate following vasectomy. *Fertil Steril* 20:163–170.
- Freund MJ, Weidmann JE, Goldstein M, Marmar J, Santulli R, Oliveira N (1989) Microre canalization after vasectomy in man. *J Androl* 10:120–132.
- Fritz P, Weiske WH (1996) Histomorphologische Veränderungen im Bereich früherer Vasektomien. *Akt Urol* 27:128–132.
- Giovannucci E, Tosteson TD, Speizer FE, Vessy MP, Colditz GA (1992) A long-term study of mortality in men who have undergone vasectomy. *N Engl J Med* 326:1392–1398.
- Giovannucci E, Ascherio A, Rimm EB, Colditz GA, Stampfer MJ, Willett WC (1993a) A prospective cohort study of vasectomy and prostate cancer in U.S. men. *JAMA* 269:873–877.
- Giovannucci E, Tosteson TD, Speizer FE, Ascherio A, Vessy MP, Colditz GA (1993b) A retrospective cohort study of vasectomy and prostate cancer in U.S. men. *JAMA* 269:878–882.
- Goldstein M (1983) Vasectomy failure using an open-ended technique. *Fertil Steril* 40:699.
- Goldstein M (1995) *Surgery of Male Infertility*. W.B. Saunders Co., Philadelphia, p 39.
- Hallan RI, May ARL (1988) Vasectomy: how much is enough? *Br J Urol* 62:377–379.
- Haws JM, Morgan GT, Pollack AE, Koonun LM, Magnani RJ, Gargiullo PM (1998) Clinical aspects of vasectomies performed in the United States in 1995. *Urology* 52:685–691.
- Heidenreich A, Bonfig R, Wilbert DM, Strohmeier WL, Engelmann UH (1994) Risk factors for antisperm antibodies in infertile men. *Am J Reprod Immunol* 31:69–76.
- Holt BA, Higgins AF (1996) Minimally invasive vasectomy. *Br J Urol* 77:585–586.
- Jequier AM (1998) Is vasectomy of long-term benefit? *Hum Reprod* 13:1757–1759.
- John EM, Whittmore AS, Wu AH, Kolonel LN, Hislop TG, Howe GR, West DW, Hankin J, Dreon DM, Teh CZ *et al.* (1995) Vasectomy and prostate cancer: results from a multiethnic case control study. *J Natl Cancer Inst* 87:662–669.
- Jørgensen N, Giwercman A, Hansen SW, Skakkebaek NE (1993) Testicular cancer after vasectomy: origin from carcinoma *in situ* of the testis. *Eur J Cancer* 29:1062–1064.
- Kasirajan K, Govindarajan S, Erzurum VZ, Lopez J, Lopez R (1999) Synchronous laparoscopic vasectomy and hernia repair. *J Laparoendosc Ad Surg Tech A* 9:177–180.
- Kendrick JS, Ginzales B, Huber DH, Grubb G, Rubin GL (1987) Complications of vasectomies in the United States. *J Fam Pract* 25:245–248.
- Kumar V, Kaza EM, Singh I, Singhal S, Kumaran V (1999) An evaluation of the no-scalpel vasectomy technique. *BJU Int* 83:283–284.
- Leader AJ, Axelrad SD, Frankowski R, Mumford ST (1974) Complications of 2,711 vasectomies. *J Urol* 111:365–369.
- Lemack GE, Goldstein M (1996) Presence of sperm in the pre-vasectomy reversal semen analysis: incidence and implications. *J Urol* 155:167–169.
- Lesko SM, Louik C, Vezina R, Rosenberg L, Shapiro S (1999) Vasectomy and prostate cancer. *J Urol* 161:1848–1852.
- Li SQ, Goldstein M, Zhu J, Huber D (1991) The no-scalpel vasectomy. *J Urol* 145:341–344.
- McDonald SW (1996) Vasectomy review: sequelae in the human epididymis and ductus deferens. *Clin Anat* 99:337–347.
- Maatman TJ, Aldrin L, Carothers GG (1997) Patient noncompliance after vasectomy. *Fertil Steril* 68:552–555.
- Magnani RJ, Haws JM, Morgan GT, Gargiullo PM, Pollack AE, Koonin LM (1999) Vasectomy in the United States, 1991 and 1995. *Am J Public Health* 89:92–94.
- Manson JE, Ridker PM, Spelsberg A, Ajani U, Lotufo PA, Hennekens CH (1999) Vasectomy and subsequent cardiovascular disease in US physicians. *Contraception* 59:181–186.
- Massey FJ, Bernstein GSO, Fallon WM, Schumann LM, Coulson AH, Crozier R, Mandel JS, Benjamin RB, Berendes HW, Chang PC, Detels R, Emslander RF, Korelitz J, Kurland LT, Lepow IH, Quiroga J, Schmidt S, Spivey GH, Sullivan T (1984) Vasectomy and health; results from a large cohort study. *JAMA* 252:1023–1029.
- Mettlin C, Natarajan M, Huben R (1990) Vasectomy and prostate cancer risk. *Am J Epidemiol* 132:1956–1961.
- Mo ZN, Huang X, Zhang SC, Yang JR (1995) Early and late long-term effects of vasectomy on serum testosterone, dihydrotestosterone, luteinizing hormone and follicle-stimulating hormone levels. *J Urol* 154:2065–2069.
- Møller H, Knudsen LB, Lynge E (1994) Risk of testicular cancer after vasectomy: cohort study of over 73 000 men. *Br Med J* 309:295–299.
- Myers SA, Mershon CE, Fuchs EF (1997) Vasectomy reversal for treatment of the post-vasectomy pain syndrome. *J Urol* 157:518–519.
- Peterson HB, Howards SS (1998) Vasectomy and prostate cancer: the evidence to date. *Fertil Steril* 70:201–203.
- Philip T, Guillebaud J, Budd D (1984) Complications of vasectomy: review of 16 000 patients. *Br J Urol* 56:745–748.
- Piccinino LJ, Mosher WD (1998) Trends in contraceptive use in the United States: 1982–95. *Fam Plan Perspect* 30:46.
- Pryor JP (1998) Vasectomy. An effective form of contraception. *Hum Reprod* 13:1759–1760.
- Rosenberg L, Palmer JR, Zauber AG, Warshauer ME, Stolley PD, Shapiro S (1990) Vasectomy and the risk of prostate cancer. *Am J Epidemiol* 132:1051–1055.
- Rosenberg L, Palmer JR, Zauber AG, Warshauer ME, Strom BL, Harlap S, Shapiro A (1994) The relation of vasectomy to the risk of cancer. *Am J Epidemiol* 140:431–438.
- Schmidt SS (1966) Techniques and complications of elective vasectomy. *Fertil Steril* 17:467–482.
- Schmidt SS (1995) Vasectomy by section, luminal fulguration and fascial interposition: results from 6248 cases. *Br J Urol* 76:373–374.
- Schmidt SS, Free MJ (1978) The bipolar needle for vasectomy. I. Experience with the first 1000 cases. *Fertil Steril* 29:676–680.
- Schwingl PJ, Guess HA (2000) Safety and effectiveness of vasectomy. *Fertil Steril* 73:923–936.
- Shapiro EI, Silber SJ (1979) Open-ended vasectomy, sperm granuloma, and postvasectomy orchialgia. *Fertil Steril* 32:546–550.
- Skriver M, Skovsgaard F, Miskowiak J (1997) Conventional or Li vasectomy: a questionnaire study. *Br J Urol* 79:596–598.

- Smith JC (1996) Long-term complications of vasectomy. *Curr Opin Urol* 6:344–346.
- Smith JC, Cranston D, O'Brien T, Guillebaud J, Hindmarsh J, Turner AG (1994) Fatherhood without apparent spermatozoa after vasectomy. *Lancet* 344:30.
- Sokal D, McMullen S, Gates D, Dominik R (1999) A comparative study of the no scalpel and standard incision approaches to vasectomy in 5 countries. The Male Sterilization Investigator Team. *J Urol* 162:1621–1625.
- Stone N, Blum DS, DeAntoni EP, Crawford ED, Schmid K, Eisenberger MA, Berger ER, Jefferson P, Staggers F, Gambert SR (1994) Prostate cancer risk factor analysis among > 50,000 men in a national study of prostate-specific antigen (PSA). *J Urol* 151:278A.
- Verhulst AP, Hoekstra JW (1999) Paternity after bilateral vasectomy. *BJU Int* 83:280–282.
- Weiske WH (1994) Minimal invasive Vasektomie mittels Fulgurationstechnik. *Urologe B* 34:448–452.
- Weiske WH (2000) Mikrochirurgische Refertilisierung nach Vasektomie—aktueller Stand. *J Fertil Reprod* 10:7–14.
- Weiske WH, Schulze W (1996) Spermatogenese nach Vasektomie. *Urologe A Suppl.* 1:S63.
- Whyte J, Sarrat E, Torres A, Diaz P, Ortíz PP, Cisneros A, Whyte A, Mazo R (1998) Vasectomia experimental: comparacion de la estructura testicular mediante diferentes tecnicas quirurgicas. *Actas Urol Esp* 22:178–183.
- World Health Organization (1991) Noticeboard: vasectomy and cancer. *Lancet* 338:1586.
- Zhu K, Stanford JL, Daling JR, McKnight B, Stergachis A, Brawer MK, Weiss NS (1996) Vasectomy and prostate cancer: a case-control study in a health maintenance organization. *Am J Epidemiol* 144:717–722.