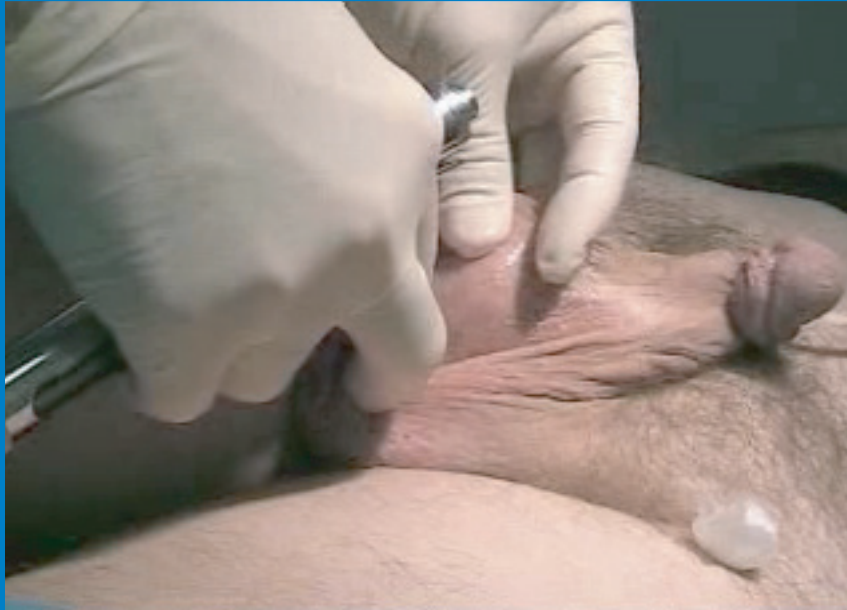
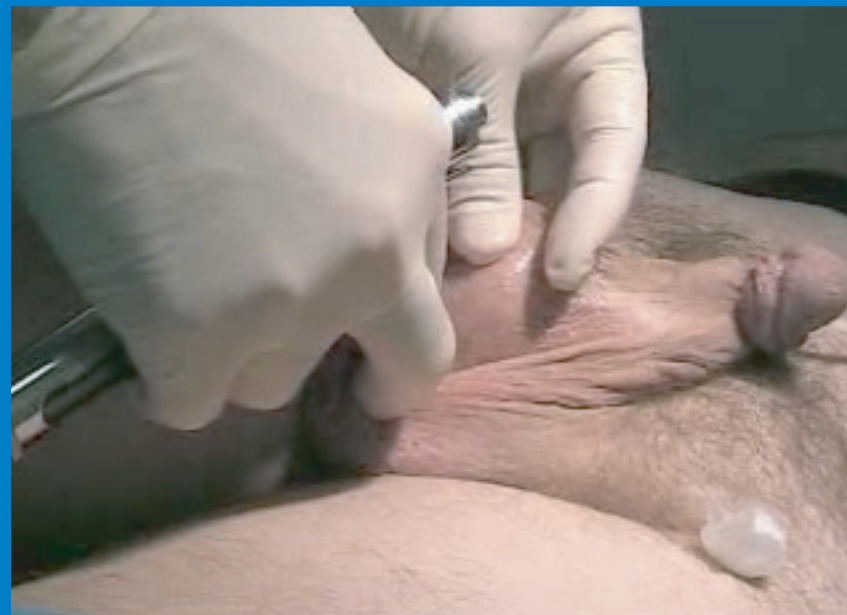
One No-Needle Anesthesia Technique For No-Scalpel Vasectomy

www.ameditech.com



1. The scrotal skin is cleansed with alcohol. The right vas deferens is isolated using standard No-Scalpel Vasectomy 3 finger technique.



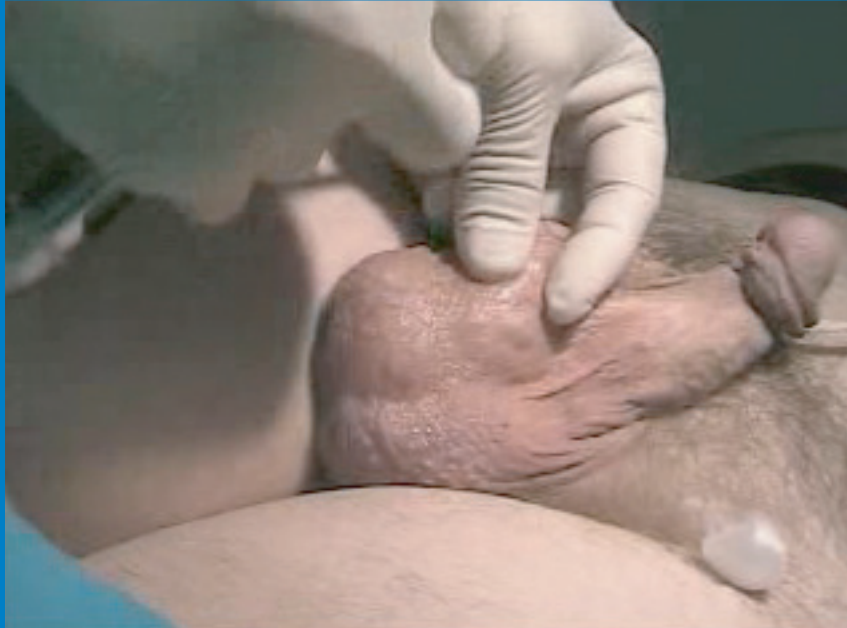2. The first injection is made over the right vas deferens just below the intended vasectomy entry site, at the junction of the upper 1/3 and lower 2/3 of the scrotum on the median raphe.

Page 1

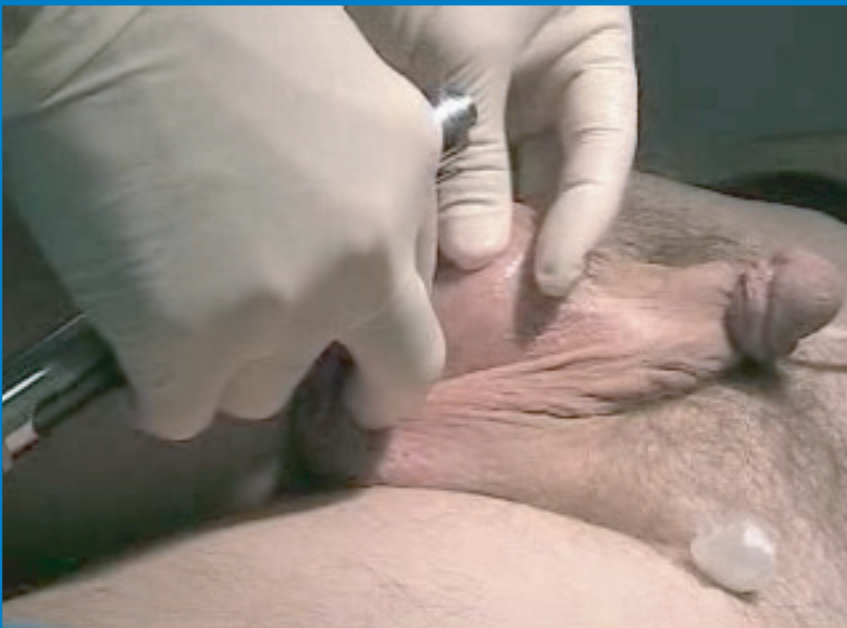Photographs courtesy of Ronald Weiss, M.D.

One No-Needle Anesthesia Technique for NSV

www.ameditech.com



3. Without releasing the 3-finger hold, the injector lever is recocked against the physician's left wrist.



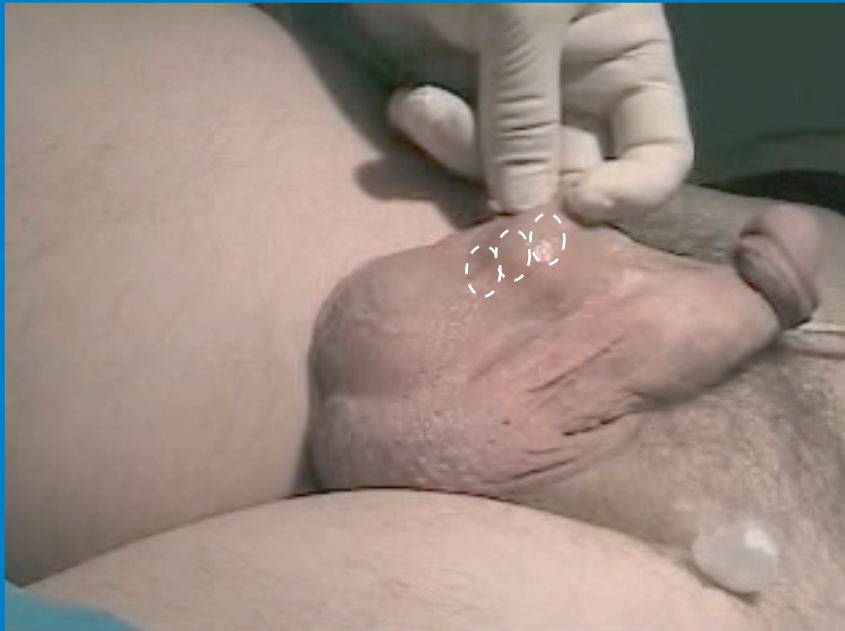4. A second injection is made over the right vas very close to the injection site

Page 2

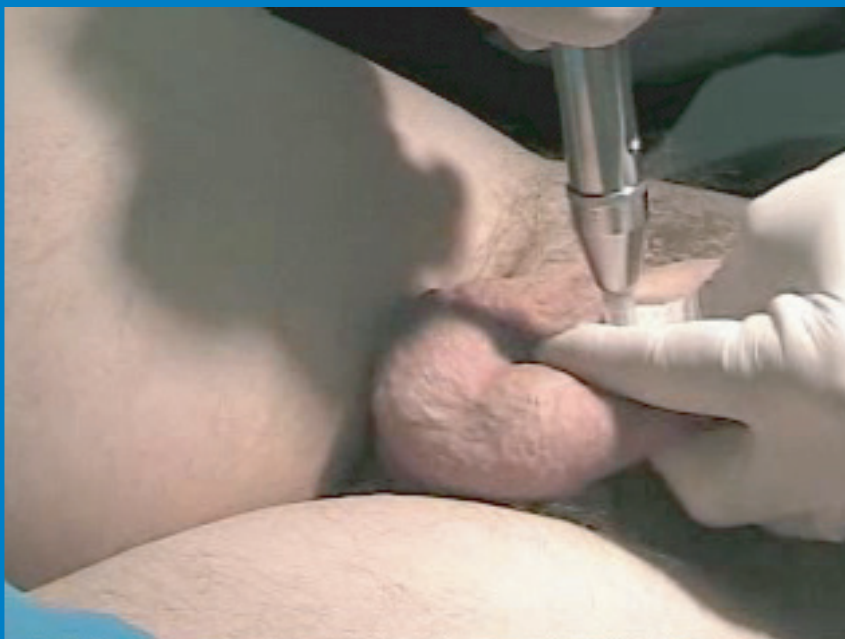Photographs courtesy of Ronald Weiss, M.D.

One No-Needle Anesthesia Technique for NSV

www.ameditech.com



5. Recocking is repeated and a third injection is made over the right vas just above the entry site along the vas. Note the three injection sites (white rings).



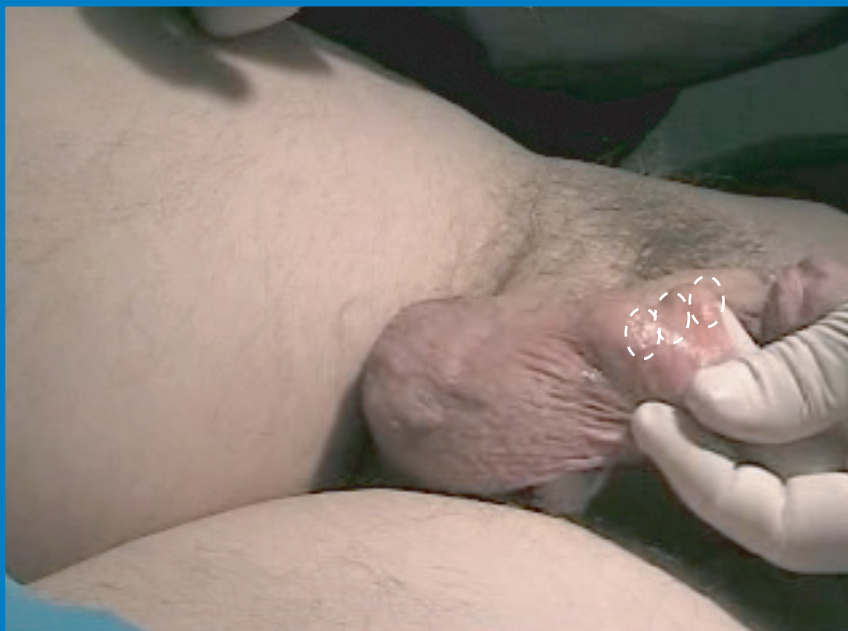6. The left vas deferens is isolated using standard 3-finger technique and the process of three injections is repeated on the left side.

Page 3

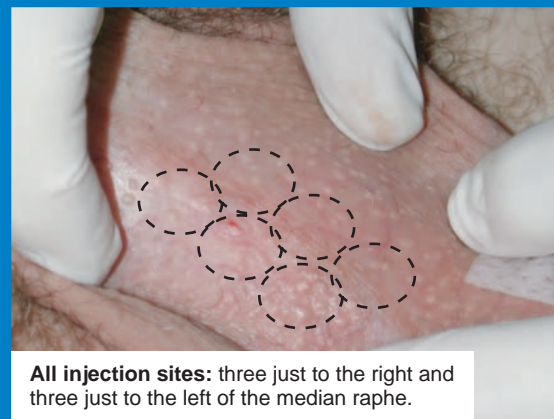
Photographs courtesy of Ronald Weiss, M.D.

One No-Needle Anesthesia Technique for NSV

www.ameditech.com

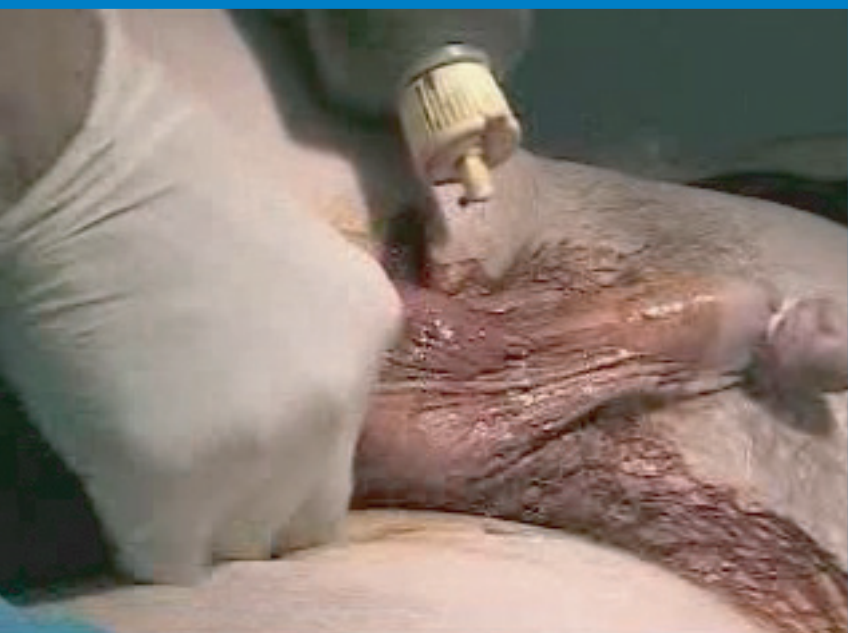

7. The three injection sites on the left side.



All injection sites: three just to the right and three just to the left of the median raphe.

8. The scrotum is then prepped for standard no-scalpel vasectomy surgical approach.



Page 4