



NO-SCALPEL, NO-NEEDLE VASECTOMY

MARA A. MONOSKI, PHILIP S. LI, NEIL BAUM, AND MARC GOLDSTEIN

Vasectomy is the safest and most dependable method of permanent contraception available to men today. More than 500,000 vasectomies are performed in the United States and more than 55,000 in Canada each year. Of American married couples, 7% to 10% choose vasectomy as their form of birth control. This has made vasectomy the most common urologic procedure in North America.¹⁻³

Although vasectomy is a safe and simple procedure for those who are well-trained, it can be technically challenging. Most contemporary surgeons and urologists have never been formally educated on how to perform a conventional vasectomy through a 2 to 3-cm incision or the newer no-scalpel vasectomy made through a 2 to 3-mm puncture wound on the scrotum. Many are forced to learn the procedure by trial and error during or after their residency training. Therefore, many urologists develop their own techniques that stray from more superior methods that have fewer complications and lower failure rates and may be accomplished with little or no pain. Kendrick and associates⁴ illustrated how vasectomy performed by inexperienced hands leads to an increased incidence of complications such as bleeding, hematoma and infection.

We discuss the no-scalpel vasectomy and no-needle vasectomy, a unique and nearly painless technique for anesthetizing the scrotal skin and vas. Using a jet injector (MadaJet, Mada Medical Products, Carlstadt, NJ), the anesthetic solution is sprayed through the skin and around the vas using a high-pressure injector that patients have described as a "gentle snap of a rubber band" against

the scrotal skin.^{1,5} The no-needle jet injection is a simple, effective, and safe technique that delivers excellent local anesthesia for vasectomy with high patient satisfaction. We believe this technique may reduce men's fear of the pain associated with the needle puncture involved in vasectomy and, in conjunction with the no-scalpel vasectomy, will likely enhance the popularity of vasectomy worldwide.

HISTORY

In 1974, Dr. Shunqiang Li developed the no-scalpel vasectomy in China. Goldstein *et al.*⁶ performed the first no-scalpel vasectomy in the United States in 1985 and published their experience using this technique in 1991. Since then, millions of men have undergone no-scalpel vasectomy in the United States and Canada. No-scalpel vasectomy has become the technique of choice for surgeons in North America.² It has also been popularized worldwide because of its minimally invasive approach, which reduces the incision size, procedure time, pain, bleeding, and post-operative complications compared with conventional scalpel vasectomy.^{2,3,6-11} Since 1975, more than 15 million men have undergone no-scalpel vasectomy with a 10-fold reduction in complications compared with standard vasectomy.⁹

INDICATIONS AND CONTRAINDICATIONS

It must first be determined whether vasectomy is an appropriate option for the patient. Information regarding the patient's age, reason for vasectomy, and relationship status should be documented. It is important to discuss with the patient alternative methods of contraception, risks of the procedure, which include failure, and possible complications such as bleeding and infection. The physician must ensure that the patient considers the procedure permanent and have him sign an informed consent form before undergoing vasectomy.^{3,12,13} Men should also be encouraged to discuss this decision with their partner.

On physical examination, the presence of bilateral vas deferens should be assessed. The testes should be examined for any masses, because men seeking vasectomies are in the age range for testic-

From the Department of Urology and Center for Male Reproductive Medicine and Microsurgery, Cornell Institute for Reproductive Medicine, Weill Medical College of Cornell University, New York Presbyterian Hospital of Columbia and Cornell, New York, New York; Department of Urology, Tulane Medical School; and Department of Urology, Louisiana State University Medical School, New Orleans, Louisiana

Reprint requests: Marc Goldstein, M.D., Department of Urology, Weill Medical College of Cornell University, New York Presbyterian Hospital of Columbia and Cornell, Box 580, 525 East 68th Street, New York, NY 10021-4873. E-mail: mgoldst@med.cornell.edu

Submitted: November 10, 2005, accepted (with revisions): March 7, 2006

ular cancer. This is also an opportunity for doctors to show men how to perform a testicular self-examination.³

Certain conditions in which vasectomy should be delayed include active scrotal skin infections, epididymitis/orchitis, and balanitis because of the increased risk of postoperative infections. Men who have large varicoceles, hydroceles, or inguinal hernias may undergo vasectomy simultaneously with the repair of these other conditions. If an intrascrotal mass is present, a workup, including scrotal ultrasonography, must be performed before vasectomy to rule out malignancy. Caution should be used in men with a history of previous scrotal surgery and cryptorchidism, because it can be very difficult to locate the vas, making no-scalpel access more difficult. Men who have undergone prior varicocelectomy, especially with a non-artery-sparing or nonmicroscopic technique, are at risk of postvasectomy testicular atrophy if the testicular artery was ligated at varicocelectomy and they are dependent on the vasal artery for the blood supply to the testis. In these men, vasectomy should only be performed microsurgically, with preservation of the vasal (deferential) arteries and veins.

Situations in which vasectomy should not be done include men with bleeding diatheses because they are at risk for hematomas, which can grow to frightening size. Young men or men who are not in permanent relationships should consider other forms of birth control.

ANESTHESIA

Until recently, anesthesia for vasectomy was administered into the scrotal skin and vas with a needle. However, the initial needle puncture is commonly the most anxiety-provoking aspect of the procedure for the patient. Now, a new and virtually painless application of anesthesia has been introduced that has revolutionized performance of vasectomy.^{1,14} The purpose of no-needle jet injection, also called no-needle vasectomy, is to simplify the application of anesthesia for vasectomy, allay the fear of needles, and make vasectomy less painful.

NEEDLE INJECTION

The first steps are to shave the scrotum, secure the penis against the patient's lower abdomen, and prepare the surgical area with Betadine. The next step involves bringing one vas to the scrotal surface at the median raphe using the three-finger technique to stabilize the vas (Fig. 1A).

For right-handed physicians, the left thumb is placed on the median raphe halfway between the base of the penis and the superior aspect of the testes. The left middle finger finds the vas on its posterior surface and brings it up to the median

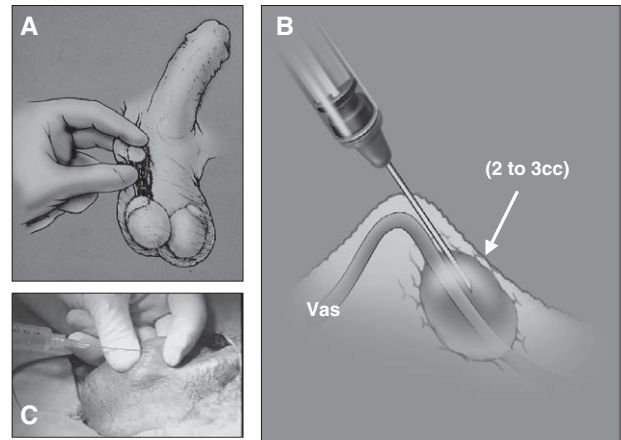


FIGURE 1. (A) Three-finger technique to isolate vas from vessels in spermatic cord. (B) Local vasal nerve block: raise wheal at skin surface, inject 2 to 3 mL of anesthetic solution along vas approximately 2 to 3 cm proximal to vasectomy site. (C) Needle injection of anesthesia using three-finger technique. Parts A and B were modified, with permission, from Weiss RS, and Li PS: No-needle jet anesthetic technique for no-scalpel vasectomy. *J Urol* 173(5): 1677-1680, 2005.

raphe so that it is caught between the thumb and middle finger (isolating it away from the rest of the testicular vessels in the spermatic cord). The index finger is then placed on the anterior surface of the vas proximal to where the other two fingers have the vas secured.

The standard anesthesia technique for no-scalpel vasectomy is a local vasal nerve block using a needle injection with 1% to 2% lidocaine without epinephrine (Fig. 1B,C). Initially, a wheal is raised at the skin surface. Then, the needle is advanced deeply and proximally along the perivasal sheath while injecting 2 to 3 mL of anesthetic solution. We suggest a single injection instead of multiple injections to reduce the risk of injury to the testicular vessels and subsequent hematoma.^{1,6,15}

NO-NEEDLE JET INJECTION (NO-NEEDLE VASECTOMY)

The jet injection technique uses an instrument that generates a high-pressure spray that forces anesthetic solution through the skin, vas, and surrounding vasal tissues providing complete anesthetic block of the vas (Fig. 2A). It provides near perfect, painless anesthesia, almost never requiring application of additional anesthetic.^{1,5} Currently, MadaJet (US \$568 to \$662/set) is the brand used by our institution to perform no-needle vasectomy. Numerous jet injectors are available that are used in other fields of medicine. Some of these include the Syrijet Mark II (US \$1649/set, Keystone Industries, Cherry Hill, NJ) and the French-made DermoJet (US \$550/set, Akra Dermojet, Pau, France). The Syrijet Mark II is primarily used by

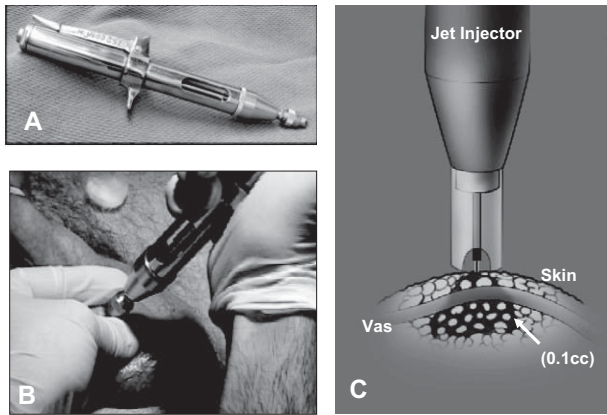


FIGURE 2. (A) Jet injector. (B) Jet injection of anesthesia along median raphe using three-finger technique. (C) Jet injection dispersion pattern. Part C was modified, with permission, from Weiss RS, and Li PS: No-needle jet anesthetic technique for no-scalpel vasectomy. *J Urol* 173(5): 1677–1680, 2005.

dentists and requires a special anesthetic cartridge. Currently, MadaJet is the most reliable and appropriate for vasectomy.

No-needle jet injection has multiple advantages.¹ It is less traumatic to the tissues, uses only one tenth the volume of anesthetic solution (approximately 0.1 mL/spray), and has a much more profound and faster onset of action (seconds versus minutes). The incidence of hematoma using jet injection is very low and, in experienced hands, can be negligible.^{1,16} This was illustrated by Weiss *et al.*¹⁴ who had no hematomas develop after performing no-needle vasectomy on 1391 patients in 2004.

All the components of the jet injector are autoclavable for proper sterilization. Approximately 4 to 5 mL of anesthetic solution is used to load the filling chamber. The jet injector assembly is affixed to the filling chamber. A spacer with a notch at the tip of the jet injector fits over the vas and allows enough distance for the spray of anesthesia to spread out in a cone-shaped distribution before and just after penetrating the skin. The instrument is then primed by pumping the lever and firing several times to ensure it is functioning properly.

The patient is positioned and shaved as described previously. The right vas is grasped using the three-finger technique and brought to the surface of the scrotal skin at the median raphe. It is important to wear a finger protector over the middle finger of the nondominant hand behind the vas to prevent accidental injection of anesthesia through the scrotum into the practitioner's finger. This will only occur if the vas is not trapped in the groove of the injector. Normally, if the injection is properly directed into the vas wall, it will not penetrate through the posterior scrotal wall.

The skin over the median raphe only has to be swabbed with an alcohol pad before the administration of anesthesia. The groove in the spacer on the tip of the jet injector is placed firmly over the right vas on the median raphe at the junction of the upper one third and lower two thirds of the scrotum (Fig. 2B). Three sprays of anesthesia are applied along the left lateral aspect of the median raphe approximately 4 to 5 mm apart. Then, the left vas is brought to the same position at the median raphe, except that three injections are applied to the right lateral aspect of the median raphe adjacent to the previous injections. This crossed anesthesia along the median raphe gives a wider anesthetic field to the skin and underlying tissues and ensures patient comfort throughout the skin puncture and tissue manipulation during no-scalpel vasectomy.

The jet injection is very effective because the anesthesia solution disperses in an inverted cone-shape distribution, affecting all the tissues to a depth of 4 to 4.5 mm from the skin surface (Fig. 2C). The anesthetic solution is quickly absorbed by the tissue around the vas, with much less trauma and pain than after needle injection. No skin wheal or local edema is present at the injection site, making no-scalpel vasectomy easier to perform. The injection sites are recognized by small blanched discolorations of the skin.

Studies have been performed analyzing the pain scores involved in the application of anesthesia for vasectomy and the vasectomy itself. Using a visual analog scale, Weiss and Li¹ found that the average pain score for the jet injection of anesthesia was 1.71 of 10 (range 1 to 7.40, median 1.3). The average visual analog scale pain score for the vasectomy that was subsequently performed after jet injection was 0.66 of 10 (range 0 to 6.60, median 0.2).¹

The area is then prepared with Betadine and draped in standard surgical fashion. At this time, the tip of the jet injector should be soaked in a disinfectant solution (MadaCide is recommended by Mada Medical Products) to adequately sterilize it before its use on the next patient.

SURGICAL PROCEDURE

Vasectomy consists of two components: access to the vas and vasal occlusion. It is important to understand that the no-scalpel vasectomy is one method for gaining access to the vas and conventional vasectomy is another option. Once the vas is delivered out of the scrotum, the method of vasal occlusion can vary depending on physician preference.

ACCESS TO THE VAS

Conventional vasectomy involves making either bilateral transverse incisions high on the scrotum

or the preferred single vertical incision on the median raphe to expose the vas. At this point, any of the many techniques for vasal occlusion can be used. Once this has been accomplished, the scrotal incisions can either be left open if they are less than 1 cm long or closed with a few interrupted absorbable sutures.

The no-scalpel vasectomy has been proved a superior method of gaining access to the vas compared with conventional vasectomy. It is an elegant technique for exposing the vas through a tiny puncture wound 2 to 3 mm in length, with negligible pain and trauma to the surrounding tissues.³ Not only can it be performed faster, but the incidence of hematomas and infections is decreased and the postoperative recovery time is shorter.¹⁷

The first step is to fix one of the vas against the scrotal skin at the median raphe using the three-finger technique. A ring-tipped fixation clamp is used to grasp the vas through the skin. One blade of a sharp, pointed, curved mosquito hemostat (dissecting forceps) is used to puncture through the scrotal skin for 5 mm or to the lumen of the vas. The instrument is removed, and both tips of the dissecting forceps are reinserted into the puncture site and spread transversely across the vas to strip the skin and vasal sheath away from the bare vas.

After spreading the tissue on top of the vas adequately, one blade of the dissecting forceps is used to pierce the vas to the lumen. The blade inside the vas lumen is rotated 180° and then the vas is lifted up and out through the scrotal skin, at the same time releasing the ring clamp. This will allow the vas to be pulled up and out of the scrotal skin. The exposed vas is regripped with the ring clamp to keep it from falling back into the scrotum. Approximately 1 cm of the vas is dissected free from its sheath longitudinally with the dissecting forceps. The vas is occluded using any of the techniques described below.

The contralateral vas is brought through the same puncture site and is occluded using an identical approach. At the end of the procedure, it is necessary to inspect the ends of the vas and the wound for any bleeding to prevent hematoma formation. It is seldom necessary to close the puncture wound with sutures. It is merely compressed for 1 minute and then covered with antibiotic ointment.

VAS OCCLUSION

Numerous techniques for vasal occlusion exist and are used throughout the world. These include ligation of the vas with either suture or clips, excision of a segment of vas of various lengths, folding back the end of the vas onto itself, fascial interposition between the cut ends of the vas, and cautery of the lumen of the vas (thermal or electric).¹⁰

These techniques have been used alone and in various combinations. However, it has been difficult to determine which method or combination of methods is truly most effective to prevent recanalization and vasectomy failure because of the heterogeneity of study design, surgical technique used, and assessment of results.¹⁰

The method used most often worldwide is suture ligation and excision. This is especially true for economically challenged areas, because it is the simplest and quickest technique to perform, with the least amount of materials needed.¹⁸ However, this technique used alone is the least effective and has a failure rate of approximately 1% to 5%.² This could be because of necrosis at the ends of the vas distal to the ligature, allowing recanalization to occur more easily. Some studies have shown that the addition of fascial interposition, in which the vasal sheath is pulled back over the cut end of the vas and secured in place, increases the effectiveness of vasal occlusion by ligation and excision.¹⁰ Nevertheless, fascial interposition is a more complicated technique and increases the time needed to perform vasectomy.

The most effective technique is thought to be cautery combined with fascial interposition. Data collected from multiple studies have shown a failure rate of 0% to 1.2%.¹⁰ However, it has been debated whether thermal versus electric cautery is more effective. Several studies have suggested thermal cautery to be superior. One study in particular showed histologic proof of the ability of thermal cautery over electric cautery to occlude the vas, as evidenced by fewer cases of vasitis nodosa and spermatic granuloma.¹⁹ Even with this information, the question remains whether cautery alone is better than ligation and excision.

A recent survey of vasectomists in the United States looked at the use of different vasal occlusion methods specifically in America. The survey found that 70% used cautery to occlude the vas during vasectomy. The second most popular occlusion technique is ligation, used by approximately 60% of practitioners. Additionally, about one quarter of all vasectomists apply metal clips to the vas.²⁰

RESULTS AND COMPLICATIONS

The most common complications associated with vasectomy are hematoma formation and infection. On average, 2% of conventional vasectomies are complicated by the formation of a hematoma postoperatively.⁴ With the no-scalpel technique, the incidence of hematoma is less than 0.5%. Infection is a relatively rare occurrence when vasectomy is performed under sterile conditions. However, when it

does occur, it is usually associated with an underlying hematoma.³ It is well documented that the experience of the physician is the most important factor in the incidence of complications encountered after vasectomy.⁴

Sperm granulomas form when sperm leak from the testicular side of the vas, leading to an inflammatory reaction. Some studies have shown that the formation of sperm granulomas can have a positive effect on patency rates in vasectomy reversals by decreasing the pressure-induced damage on the epididymis.²¹ However, sperm granulomas can lead to unacceptably high recanalization and vasectomy failure rates.³

Most pressure produced on the testicular side of the vas after occlusion is transmitted to the epididymis and efferent ductules, but not the seminiferous tubules. Minimal damage more distally in the system has been shown by electron microscopic studies of the testis, demonstrating areas of basal lamina thickening and spermatogenesis disruption.²² However, Leydig cells remained normal, with no injury to their structure or function.³

Several possible long-term effects associated with vasectomy include chronic testicular/epididymal pain, testicular dysfunction, vasitis nodosa, and chronic epididymal obstruction.² Approximately 1 in 1000 men will experience chronic testicular/epididymal pain postoperatively.²³ Possible treatments for this bothersome complication include vasectomy reversal, open-ended vasectomy, or even total epididymovasectomy.

Systemic effects such as the development of anti-sperm antibodies can occur secondary to breakdown of the blood-testicular barrier. It has been postulated that the formation of immune complexes can occur, ultimately leading to atherosclerosis. However, multiple studies have failed to show the formation of these immune complexes or their deposition in vasectomized men.^{2,3}

There has also been a concern that vasectomy may increase the incidence of prostate and testicular cancer. This initial perception was probably a result of a selection bias because men undergoing vasectomy were seeing a urologist and were more likely to be screened, and therefore diagnosed, with urologic cancer. Many studies have shown this to be false. Men can be comfortable that vasectomy will not put them at a greater risk of genitourinary cancer.³

Before a man can start having unprotected sex after vasectomy, he must be completely azoospermic. At least one to two semen analyses 4 to 6 weeks apart should be obtained 12 weeks after surgery. A repeat vasectomy should be performed if any motile sperm are found in the ejaculate 3 months after surgery.²

OPPORTUNITIES AND MARKETING POTENTIAL

Although no-scalpel vasectomy was introduced to the United States more than 20 years ago, many urologists still do not know how to perform this technique properly. Now, with the addition of no-needle vasectomy for the application of local anesthesia, there is a wonderful opportunity to provide men with a virtually painless and extremely effective form of permanent contraception.

Vasectomy is an excellent opportunity for additional revenue for any urologist. Physicians can charge approximately U.S. \$650 per vasectomy, which is commonly a cash-pay procedure compared with the U.S. \$100 billed for a new level 3 patient visit. Vasectomy takes only 10 to 20 minutes to perform, resulting in a tremendous revenue/time ratio. If a physician can add five vasectomies a month by increased exposure on the Internet, this translates into a profit of U.S. \$3000 to 4500/mo or US \$40,000 to 55,000 annually. Another advantage to performing more vasectomy procedures is that urologists can increase their practice by additional patients and referrals from the patients' friends and family with other urologic conditions.

ACKNOWLEDGMENT. To Drs. Ronald Weiss and Doug Stein in pioneering the use and acceptance of no-scalpel and no-needle vasectomy and for sharing their experiences with us and to Dr. Ronald Weiss for allowing us to use some of his surgical images in Figures 1 and 2.

REFERENCES

1. Weiss RS, and Li PS: No-needle jet anesthetic technique for no-scalpel vasectomy. *J Urol* 173: 1677-1680, 2005.
2. Goldstein M: Surgical management of male infertility and other scrotal disorders, in Walsh PC, Retik AB, Vaughan ED, *et al* (Eds): *Campbell's Urology*, 8th ed. New York, WB Saunders, 2002, pp 1541-1547.
3. Schlegel PN, and Goldstein M: Vasectomy, in Goldstein M (Ed): *Surgery of Male Infertility*. New York, WB Saunders, 1995, pp 35-45.
4. Kendrick J, Gonzales B, Huber D, *et al*: Complications of vasectomies in the United States. *J Fam Prac* 25: 245-248, 1987.
5. Wilson CL: No-needle anesthetic for no-scalpel vasectomy. *Am Fam Physician* 63: 1295, 2001.
6. Li S, Goldstein M, Zhu J, *et al*: The no-scalpel vasectomy. *J Urol* 145: 341-344, 1991.
7. Viladoms JM, and Li PS: Vasectomy sin Bisturi. *Arch Esp Urol* 47: 695-701, 1994.
8. Kaza RM, Singh I, Singhal S, *et al*: An evaluation of the no-scalpel vasectomy technique. *BJU Int* 83: 283-284, 1999.
9. Nirathpongporn A, Huber D, and Krieger JN: No-scalpel vasectomy at the King's birthday vasectomy festival. *Lancet* 335: 894-895, 1990.
10. Labrecque M, Defresne C, Barone MA, *et al*: Vasectomy surgical techniques: a systematic review. *BMC Med* 2: 21-33, 2004.
11. Skiver M, Skovsgaard F, and Miskowiak J: Conventional or Li vasectomy: a questionnaire study. *BJU Int* 79: 596-598, 1997.

12. Haws JM, and Feigin J: Vasectomy counseling. *Am Fam Physician* 52: 1395–1399, 1995.
13. Schmidt SS: Vasectomy. *Urol Clin North Am* 14: 149–154, 1987.
14. Weiss RS, Li PS, and Goldstein M: No-needle jet anesthetic technique for the no-scalpel vasectomy (abstract). *Can J Urol* 12: 2664, 2005.
15. Li PS, Li SQ, Schlegel PN, *et al*: External spermatic sheath injection for vasal nerve block. *Urology* 39: 173–176, 1992.
16. Weiss RS, and Li PS: No-needle jet anesthetic technique for the no-scalpel vasectomy (abstract). *J Urol* 173: 367–368, 2005.
17. Sokal D, McMullen S, Gates D, *et al*: The male sterilization investigator team: a comparative study of the no scalpel and standard incision approaches to vasectomy in 5 countries. *J Urol* 162: 1621–1625, 1999.
18. Labrecque M, Pile J, Sokal D, *et al*: Vasectomy surgical techniques in South and South East Asia. *BMC Urol* 5: 10–19, 2005.
19. Schmidt SS, and Minckler TM: The vas after vasectomy: comparison of cauterization methods. *Urology* 40: 468–470, 1992.
20. Haws JM, Morgan GT, Pollack AE, *et al*: Clinical aspects of vasectomies performed in the United States in 1995. *Urology* 52: 685–691, 1998.
21. Silber SJ: Sperm granulomas and reversibility of vasectomy. *Lancet* 2: 588–589, 1977.
22. Jarow JP, Budin RE, Dym M, *et al*: Quantitative pathological changes in the human testis after vasectomy. *N Engl J Med* 313: 1252–1256, 1985.
23. McConaghy P, Paxton LD, and Loughlin V: Chronic testicular pain following vasectomy. *Br J Urol* 77: 328, 1996.